

Morphological alterations in skeletal muscle of spontaneously hypertensive rats.

Noelina Hernández¹, Sonia H. Torres¹, Mercedes Losada² y Héctor J. Finol³.

¹Institute of Experimental Medicine, Section of Muscle Adaptation;

²José María Vargas Medical School, Faculty of Medicine and

³Center for Electron Microscopy, Faculty of Science. Central University of Venezuela, Caracas, Venezuela.

Key words: Skeletal muscle, muscle capillaries, histochemistry, ultrastructure, fibrosis.

Abstract. The Extensor digitorum longus (EDL) and the soleus muscles of spontaneously hypertensive rats (SHR) were studied in comparison with those of their normal counterparts, the Wistar Kyoto (WKY) rats. Quantitative assessment of capillaries and muscle fibre typing was done with optical microscopy, while the study of capillary abnormalities was performed by ultrastructural observation. There were no differences in fibre type proportion or in capillarity indexes between the SHR and the control rats. A reduction in the area of IIB fibres was found in the EDL muscle of the hypertensive animals. The ultrastructural study showed abnormalities in the capillaries of both muscles in SHR, the cross section of the endothelial cells was enlarged; there was irregular distribution of caveolae and pinocytic vesicles, the capillary basement membrane showed irregular width, with parts engrossed and reduplicated. Some pericytes were prominent. There were macrophages present in the interstitial space. In some muscle fibres there was disorganization of the sarcomere structure, swelling of the sarcotubular system, abundant autophagic vacuoles, and proliferative satellite cells. There were abundant collagen fibrils. The presence of cellular rests, autophagic vacuoles and loss of sarcolemma indicated necrosis. It can be concluded, that in SHR, muscle capillaries showed alterations that may be the substrate of functional rarefaction, although anatomical rarefaction (number reduction) could not be demonstrated. In EDL and soleus muscles of SHR, signs of a mild myopathy with focal fibrosis were present.

Alteraciones morfológicas en el músculo esquelético de ratas espontáneamente hipertensas.

Invest Clin 2008; 49(1): 79 - 91

Palabras clave: Músculo esquelético, capilares musculares, histoquímica, ultraestructura, fibrosis.

Resumen. Se estudiaron los músculos Extensor digitorum longus (EDL) y soleus de ratas espontáneamente hipertensas (SHR), comparándolas con ratas normotensas Wistar Kyoto (WKY). La evaluación cuantitativa de los capilares y la clasificación de las fibras musculares se hizo con microscopía de luz, mientras que el estudio ultraestructural permitió visualizar cambios morfológicos. No se encontraron diferencias en la proporción de los tipos de fibras, o en los índices de capilaridad entre las ratas controles y las SHR. Una reducción del área de las fibras IIB se encontró en el músculo EDL de las SHR. El estudio ultraestructural mostró anormalidades en los capilares de ambos músculos en las SHR; en las secciones transversales de células endoteliales se observó engrosamiento del citoplasma, además distribución irregular de caveolas y vesículas pinocíticas, la membrana basal capilar mostró una anchura irregular, con algunas partes engrosadas y reduplicadas. Algunos pericitos fueron prominentes. En el espacio intersticial se encontraron macrófagos. En algunas fibras se hallaron sarcómeros estructuralmente desorganizados, el sistema sarcotubular hinchado, abundantes vacuolas autofágicas, y células satélites proliferativas. Las fibrillas de colágeno fueron abundantes. La presencia de restos celulares, vacuolas autofágicas y la pérdida del sarcolema, indicaron necrosis muscular. Se puede concluir que, aun cuando no se demostró la rarefacción anatómica (disminución numérica) en las SHR, los capilares musculares estaban alterados, lo cual puede ser el sustrato de la rarefacción funcional. En los músculos EDL y soleo de las SHR, los signos de una miopatía leve con fibrosis focal estuvieron presentes.

Received; 07-03-2007. Accepted: 26-06-2007.

INTRODUCTION

Capillary alteration in tissues can be evaluated by the reduction of their number (anatomical rarefaction), or by their functional or morphological alterations that affect their permeability and interchange of blood borne substances (functional rarefaction). In skin or conjunctiva, capillaries can be studied in vivo evaluating their number and reaction to appropriate stimuli, but this is not possible in skeletal muscle with-

out using invasive techniques. In a muscle biopsy it is possible to prepare sections and count capillaries marked by histochemical techniques, and also to use ultrastructural qualitative examination to see if capillaries, that may be present in normal numbers, show morphological alterations.

Microvascular anatomical rarefaction has been considered as a hallmark in hypertension. Decrease in number of arterioles and capillaries occur in cardiac and skeletal muscle, cutaneous circulation, intestine

and conjunctiva (1). Functional rarefaction, expressed as closure of arterioles has been shown to precede loss of these vessels resulting in anatomical rarefaction (2). In a previous study, capillaries were quantified in human quadriceps muscle samples obtained by biopsy (3). The results from that investigation showed that capillary number was not reduced in muscle of hypertensive patients compared to normal subjects, although capillary damage was demonstrated at ultrastructural level observation. In patients with essential hypertension it is not possible to know at the moment of diagnosis for how long the hypertensive condition has been present. It is possible that the patients may have been in a state of functional rarefaction of microvessels, before the structural reduction of capillaries is produced, or alternatively, anatomical reduction in capillaries does not occur in this muscle. In animal models of hypertension the time of progression of the disease can be controlled. However, the results in different models are not uniform. In rats injected with deoxycorticosterone acetate and supplemented with salt load, systolic blood pressure was significantly higher at 4 weeks. When muscles were studied 7 weeks after starting the injections, no rarefaction was found, but it was demonstrable after 14 weeks of treatment (4). In spontaneously hypertensive rats (SHR), anatomical rarefaction in skeletal muscle has been found in some muscles. It has been reported in cremaster and gracilis muscles by using stereological methods (2, 5); Greene et al (6) showed capillary reduction in cremaster and spinotrapezius muscles by incubation with rhodamine-labeled Griffonia simplicifolia I lectin. In contrast, Gray (7) reported no reduction in capillary counts in spinotrapezius and other muscles stained with the alkaline phosphatase method. Another study (8) described a decrease in capillary density, but not in capillary/fibre in-

dex in soleus muscle of SHR compared to control Wistar-Kyoto rats. However, in the same study, no difference was found in capillary numbers in plantaris and extensor digitorum longus (EDL) muscles.

Skeletal muscles are formed by different types of fibres, characterized by contraction time, aerobic or anaerobic metabolism and blood supply. Therefore, the more oxidative fibres as type I and IIA, are surrounded by a higher number of capillaries than fibres IIB, that are more glycolytic. Changes of fibre type proportion have been described in muscles of hypertensive animals (4, 9) and this can also produce variation in capillary numbers. If there is an increase in proportion of anaerobic fibres, capillarity will be consequently reduced. In addition the number of capillaries in contact with each fibre type is also related to the size of the fibre: fibres with higher cross sectional area are surrounded by more capillaries. On the other hand, if there is fibre atrophy, the capillaries surrounding the fibre will be pulled together, increasing capillary density.

Spontaneously hypertensive rats (SHR) share many characteristics with human essential hypertension, and are thought to be the best model to study this disease (10), with the advantage that there are no differences in the length of exposure to the disease in a group of rats born at the same time. In the present work, the capillaries of soleus muscle (formed predominantly by type I oxidative fibres) and EDL muscle (which is mainly formed by IIB glycolytic fibres) were studied in the genetic hypertensive animals (SHR), in comparison with Wistar Kyoto (WKY) rats, which are their normotensive counterpart (10). Light microscopy observation allowed quantification of capillaries, and ultrastructural examination permitted to check if the capillaries were normal or presented alterations suggestive of functional rarefaction. In addi-

tion, skeletal muscle fibre types were classified, their area was measured and they were observed at ultrastructural level.

MATERIALS AND METHODS

A group of 12 genetic hypertensive rats (spontaneously hypertensive rats, SHR) and 12 age-matched Wistar Kyoto rats (control group, WKY), were used in the present study. The weights of the hypertensive and normotensive rats were 283 ± 8 g and 315 ± 10 g respectively ($p < 0.01$). Rats were provided with regular rat chow and housed with controlled light (12-h light-dark cycle) and temperature conditions. All rats were taken from a colony maintained at the National Health Institute Rafael Rangel, Central University of Venezuela, Caracas, Venezuela.

The rats were anesthetized with pentobarbital sodium 40 mg/kg and chloral hydrate 200 mg/kg i.p. The left carotid artery was cannulated for arterial pressure measurement. EDL and soleus muscles were removed from the left leg and the central third of them was taken for the study. The muscle sample was divided in half. One half was extended longitudinally on a cork and pinned at both ends approximately at rest length, fixed in 3% glutaraldehyde in phosphate buffer at pH 7.4 and 320 mOsmol. After fixation, the sample was diced into small blocks and postfixed in 1% OsO₄, dehydrated in ethanol, and embedded in Epon. Ultrathin sections were stained with uranyl acetate and lead citrate and observed in a Hitachi H-500 transmission electron microscope. Six blocks (2 mm length \times 1 mm diameter) were taken from each muscle sample. Three grids were prepared from each block at different depths for a total of 18 sections. All capillaries that were oriented in transverse sections were chosen for measurements of lumen and wall thickness (11). Capillaries oriented in a position suited for measurement were not

found in all the micrographs observed. On the other hand, there were not found qualitative differences between capillaries from soleus and EDL muscles, therefore the capillaries from both muscles were grouped together. Finally for the measurements of endothelial cell width and lumen diameter 18 capillaries from hypertensive and 20 from the control animals were used.

The other half of the sample was embedded in OCT (Tissue Tek II) and frozen in isopentane cooled in liquid nitrogen. Serial sections were cut in a cryostat at -20°C , and the adenosine triphosphatase (ATPase) reaction was carried out after preincubation at acid pH 4.35 (12). Capillaries were visualized with the α -amylase-PAS reaction (13).

No less than 200 fibres were classified in each muscle. In soleus muscle type I fibres stained dark and type IIa fibres were light, some IIC fibres (intermediate staining) were found but their proportion was very low (less than 0.5%) and they were not considered; in EDL three fibre types were identified: darkly stained type I fibres, medium stained type IIA fibres and light IIB fibres. Each fibre could be identified in the ATPase- and PAS-stained serial sections, therefore classification could be transferred to photomicrographs of the PAS slide, made at a final magnification X200, which were used to measure the cross sectional area of each fibre type, and capillaries adjacent to each fibre type. An area of the photomicrograph was delimited (around 200 fibres) and measured by planimetry, and fibres and capillaries were counted to calculate the mean area of the fibres, capillaries/mm², and capillaries/fibre ratio.

Results were analyzed statistically by the non-paired Student t test. The null hypothesis was rejected at a probability level of 0.05. In the tables, results are expressed as mean \pm standard deviation; in the figures, results are expressed as mean \pm standard error.

RESULTS

Blood pressure. Mean arterial pressure was significantly higher in SHR (167 ± 4 mmHg) compared to WKY rats (114 ± 8 mmHg, $p < 0.001$).

Fibre types. Fibre type proportion in soleus and EDL muscles was similar when SHR were compared to WKY rats (Fig. 1A and B).

Capillaries. In soleus and EDL muscles, capillary/fibre, capillary/mm² and capillary number adjacent to each fibre type were similar between SHR and WKY rats (Table I).

Fibre area. No difference was found in mean fibre area between the normal and hypertensive rats. However, when fibre cross sectional area was measured in each fibre

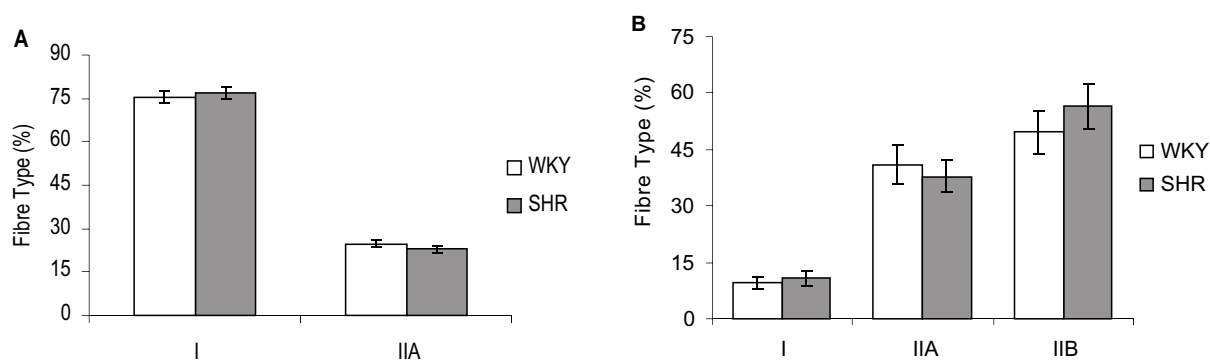


Fig. 1. Percentage of fibre types in muscles 12 control rats (WKY) and 12 spontaneously hypertensive rats (SHR). Over 200 fibres were classified in the muscle sample of each animal. A. Soleus muscle. B. Extensor digitorum longus muscle (EDL).

TABLE I
CAPILLARITY AND FIBRE CROSS SECTIONAL AREA IN THE SOLEUS AND EDL MUSCLES OF WKY RATS (CONTROL) AND SHR

		WKY	SHR
Capillary/fibre	Soleus	2.22 ± 0.34	2.01 ± 0.42
	EDL	1.96 ± 0.36	1.80 ± 0.26
Capillary/mm ²	Soleus	614 ± 212	569 ± 199
	EDL	716 ± 144	715 ± 80
Capillary adjacent to fibre I	Soleus	6.08 ± 0.71	5.85 ± 1.04
	EDL	4.85 ± 0.51	4.42 ± 0.86
Capillary adjacent to fibre IIA	Soleus	5.69 ± 0.54	5.33 ± 0.96
	EDL	5.19 ± 0.71	4.63 ± 0.88
Capillary adjacent to fibre IIB	EDL	5.87 ± 0.82	5.46 ± 0.94
Mean fibre area (μm^2)	Soleus	3922 ± 1013	3845 ± 1241
	EDL	2491 ± 599	2542 ± 416
Area type I fibre (μm^2)	Soleus	4039 ± 1086	3609 ± 924
	EDL	1588 ± 184	1618 ± 252
Area type IIA fibre (μm^2)	Soleus	3624 ± 659	3455 ± 868
	EDL	1975 ± 264	1815 ± 316
Area type IIB fibre (μm^2)	EDL	3793 ± 494	$3256 \pm 488^*$

* $p < 0.05$.

type, a significant reduction ($p < 0.05$) in type IIB fibres of the EDL muscle was found in the hypertensive rats (Table I).

Ultrastructure. In Fig. 2A, it is shown a transversal section of a muscle capillary in a normotensive WKY rat; the endothelial cell is regularly thin with evenly distributed

abundant caveolae and pinocytic vacuoles, the basement membrane is also thin; the pericyte surrounds less than 1/5 of the capillary section.

A longitudinal section of a muscle fibre in a control WKY rat is shown in Fig. 2B; Z lines are wide and straight, the sarcotubular

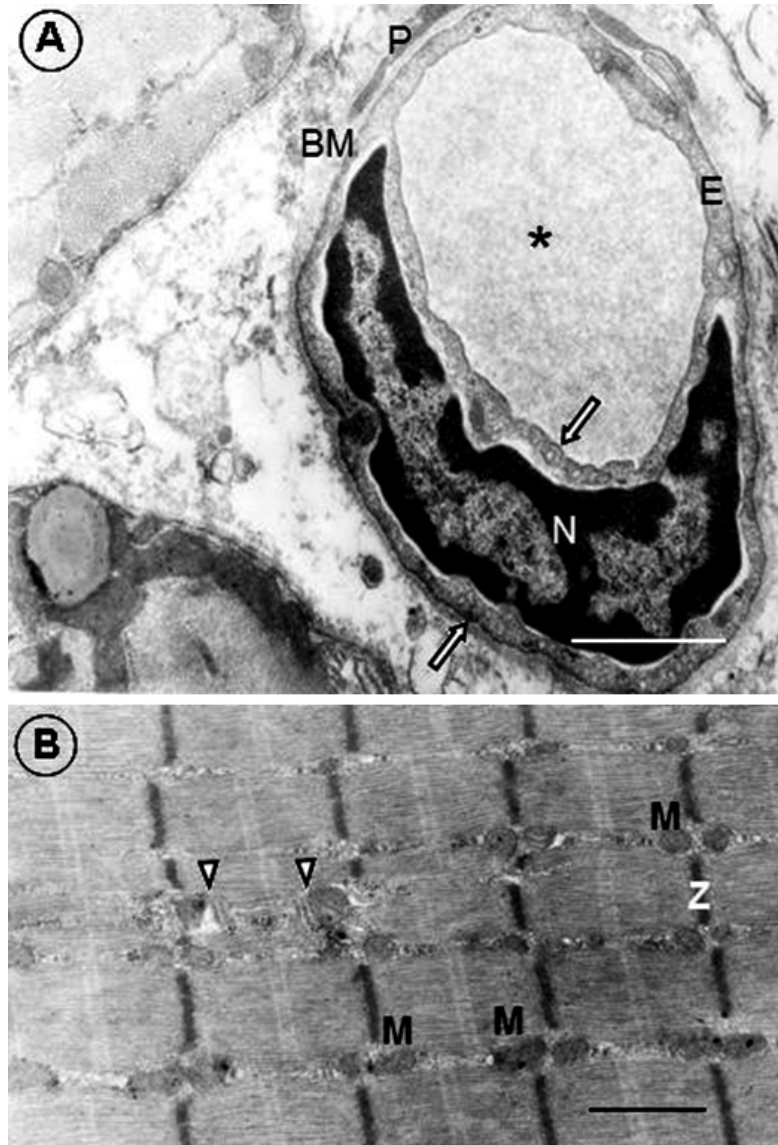


Fig. 2. Electron micrographs of muscle samples taken from two control rats (WKY). **A.** In this section a muscle capillary is shown. Capillary lumen (asterisk); basement membrane (BM); pericyte (P); endothelial cell (E); nucleus of the endothelial cell (N). Note the presence of abundant caveolae and pinocytic vesicles (arrows) in the cytoplasm of the endothelial cell. Bar = 1 μ m. **B.** Section of a normal IIA glycolitic-oxidative skeletal muscle fibre taken from soleus muscle. See two triads per sarcomere (arrowheads), abundant mitochondria (M) and thick straight Z lines. Bar = 1 μ m.

system shows two triads per sarcomere, and there are two mitochondria per sarcomere, which are features of type IIA fibres.

Some capillaries in the muscles of the SHR are partially occluded (Fig. 3A), they

show cytoplasmic endothelial areas with different width (Fig. 3A) and electron density (Fig. 4), endothelial infoldings into the capillary lumen (Figs. 3A and B), irregular distribution of vesicles (Fig. 3B), as well as

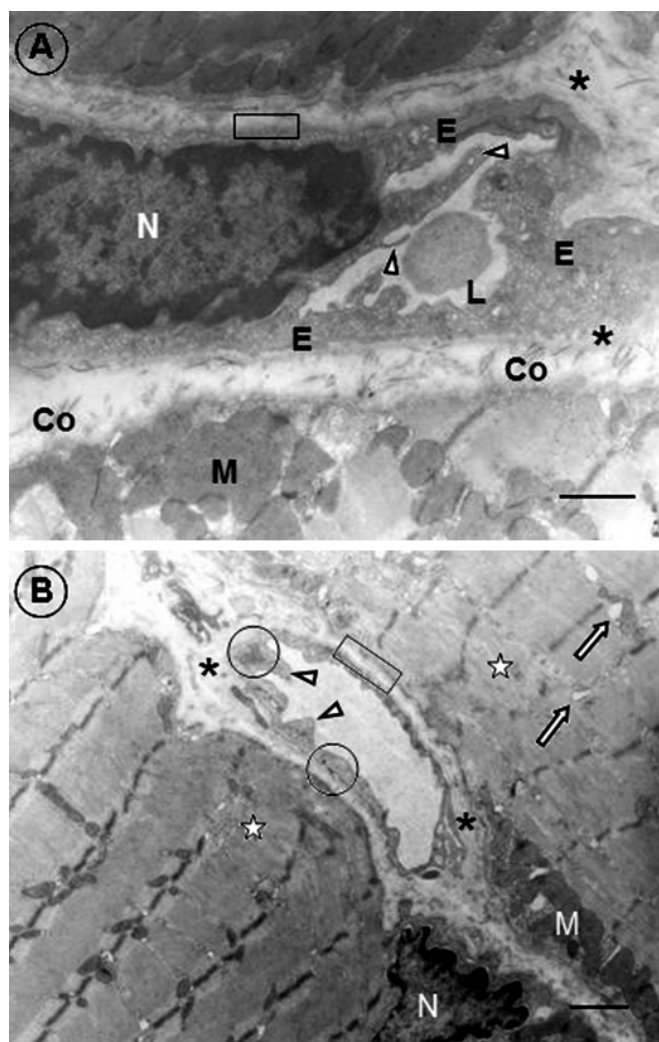


Fig. 3. Electron micrographs of muscle samples taken from two spontaneously hypertensive rats (SHR) showing capillary alterations, and in B, loss of muscle sarcomere organization. **A.** Oblique section. Capillary exhibits almost occluded lumen (L), prominent endothelial cell cytoplasm infoldings into the lumen (arrowheads) and areas of different degrees of endothelial cell thickening (E). Basement membrane shows zones of different thickness: thick (asterisks) and thin (open rectangle). Note the numerous collagen fibrils (Co). In the muscle fibre it is signalled a subsarcolemmal mitochondrion (M). Bar = 1 μ m. **B.** Longitudinal section of EDL. Note in the muscle fibres areas of loss of sarcomeric organization (stars). Nucleus (N); mitochondria (M) and swollen sarcotubular elements (arrows). In the capillary, the endothelial cell shows some areas with scarce pinocytic vesicles (circles), endothelial infoldings into the lumen (arrowheads) and areas of variable basement membrane thickness: thick and reduplicated (asterisks) and thin (open rectangle). Bar = 1 μ m.

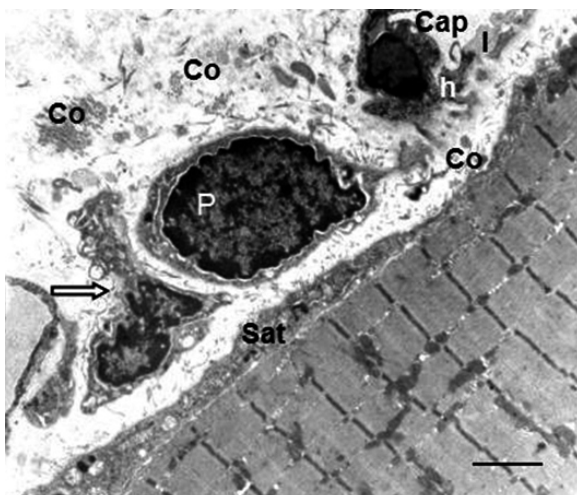


Fig. 4. Electron micrograph of a muscle sample taken from a spontaneously hypertensive rats (SHR). A part of a capillary is shown (Cap), showing different cytoplasmic density in the endothelial cell: high (h) and low (l). The pericyte is prominent (P) and a macrophage (arrow) is next to the pericyte. Next to the muscle fibre is a satellite cell in proliferative state (Sat). Abundant collagen fibrils are observed in the extracellular space (Co). Bar = 2 μm .

basement membrane of variable width, in parts thickened and sometimes reduplicated (Figs. 3A and B).

The endothelial cells width was measured in transversally sectioned capillaries. The lumen diameter was also measured and the wall to lumen ratio was calculated. There were no differences in capillary mea-

surements between EDL and soleus muscles in the control WKY or in the SHR, therefore the results of both muscles were pooled for each condition. The cross section of the capillaries was similar in the hypertensive and control group, also the lumen diameter was not different. However, the endothelial cell thickness was increased in the SHR. The wall/lumen ratio was also higher in the muscular capillaries of SHR compared to WKY control rats (Table II).

In contrast with muscles of control rats, in the SHR there were found areas of sarcomeric disorganization with loss of M line and H band (Fig. 3B) and swelling of the triad components (Fig. 3B). Abundant mitochondria are present in the subsarcolemmal and intermyofibrillar regions of the muscle fibre (Figs. 3A and 4), as well as many autophagic vacuoles (glucogenosomes) and lysosomes (Figs. 5A and B), there are nuclei with irregular shape and contours (Fig. 3B), which are usually associated with atrophy. In Fig. 4 it is observed a pericyte with a prominent and hyperchromatic nucleus, next to a macrophage, and a satellite cell in proliferative state showing mitochondria, lysosomes, rough endoplasmic reticulum and polysomes. In most of the sections numerous collagen fibrils can be seen (fibrosis) (Figs. 3A, 4, 5A and B). The presence of cellular rests, the abundance of collagen fibrils, and sarcolemmal loss (Fig. 5B) indicate that necrosis may have been present.

TABLE II
CAPILLARY AND LUMEN DIAMETER, ENDOTHELIAL CELL THICKNESS,
AND WALL TO LUMEN RATIO IN SHR AND WKY SKELETAL MUSCLES

	WKY Control ($\mu\text{m} \pm \text{SD}$)	SHR ($\mu\text{m} \pm \text{SD}$)	p level
Endothelial cell thickness	0.19 \pm 0.04	0.48 \pm 0.19	\leq 0.0003
Lumen diameter	3.92 \pm 0.94	3.87 \pm 0.94	NS
Capillary diameter	4.11 \pm 0.94	4.35 \pm 0.95	NS
Wall/Lumen ratio	0.95 \pm 0.01	0.87 \pm 0.05	\leq 0.02




Fig. 5. Electron micrographs of muscle samples taken from two spontaneously hypertensive rats (SHR), showing muscle fibre alterations and abundance of collagen fibres. A. This section shows abundance of autophagic vacuoles of glucogenosome type (squares). Observe the numerous collagen fibrils in the extracellular space (Co). Bar = 2 μ m. B. In this section it is observed an important coat of collagen fibrils covering muscle fibres (Co). Lysosomes (arrows), mitochondria (M), sarcolemmal loss (open rectangle), cellular rests (circles). Bar = 1 μ m.

DISCUSSION

The main findings in the present paper are: 1) in soleus and EDL muscle of SHR with a well established hypertensive condition, no anatomical rarefaction could be demonstrated, although capillary changes,

as degeneration and partial occlusion, that indicate capillary destruction were found at ultrastructural examination. 2) A mild myopathy was found in soleus and EDL muscles in the form of focal lesions. These results are similar to those found in the quadriceps muscle of men with essential hy-

pertension (3). In the DOCA-salt hypertensive rats, it has been demonstrated anatomical rarefaction in both soleus and EDL muscles by the use of the same histochemical methods used in the present paper to measure capillaries (4). It is interesting that salt intake alone decreased microvessel density by 16.5% in the cremaster muscle (6), and that in the obese Zucker rat model of the metabolic syndrome; microvessel rarefaction in skeletal muscle does not depend on an elevated mean arterial pressure (14). This lead to the conclusion that structural rarefaction may be associated with several factors as insulin resistance and/or activation of the renin-angiotensin-aldosterone system.

Functional rarefaction may be related to the alterations found in microvessels. A difference in reactivity to vasodilator substances has been reported in arterioles A3 and A4 in soleus and EDL muscles of SHR, which responded less than those of control rats to acetylcholine and adenosine. However, these vessels responded normally to sodium nitroprusside in contrast with those of DOCA-salt hypertensive rats (15).

Some of the alterations found in the capillaries of the SHR have been described in other pathological conditions: thickening of the capillary basement membrane is frequently observed in diseases that affect skeletal muscle as inflammatory myopathies (16, 17), arteriosclerosis obliterans (18), diabetes mellitus (19, 20). The presence of increased width of the basement membrane in SHR may indicate the presence of an inflammatory process. An increase in thickness of the endothelial cell is also described in the current paper; although the lumen diameter was not reduced, it is possible that this thickening, in addition to the presence of the endothelial infoldings into the lumen of the vessels, may reflect a decrease in the blood flow, which could be taken as functional rarefaction. The capil-

lary changes may also be a consequence of reduced flow and pressure, secondary to the remodelling of arterioles (21) with proliferation of the wall of smooth muscle cells and reduction of the arteriolar lumen (22). It has been demonstrated an inhibitory effect of pericytes on endothelial cells in cultures (23). Some prominent pericytes were found in muscle capillaries of SHR, suggesting that they may have a negative effect on capillary regeneration.

Capillary numbers may follow the transformation of fibre types, as type I fibres are surrounded by higher number of capillaries. Our results are in agreement with those of Gray (7) showing no difference in proportion of fibre types in the SHR compared to WKY control rats.

The muscle alterations found in SHR rats were: partial loss of sarcolemma, disorganization of sarcomeric structure, abundance of autophagic vacuoles and lysosomes, presence of macrophages, activation of satellite cells and the increase in collagen fibrils (fibrosis). The lesions were not very marked as to indicate a full process of degeneration-regeneration, but instead suggest a chronic damage not successfully repaired, in the form of a mild myopathy that could eventually have some effect on the activity of the animal.

The initial event of muscle degeneration is necrosis, generally triggered by disruption of the myofibre sarcolemma. Damaged muscle initiates a repair process; factors released from the injured muscle activate local inflammatory cells that produce chemotactic signals to attract circulating neutrophils, soon replaced by macrophages (24). The activation of satellite cells is produced, with proliferation and migration to the site of the lesion to form myogenic cells. Under normal conditions the repair process leads to a morphologically and functionally regenerated tissue indistinguishable from undamaged muscle. But if

the cause of injury is chronic, the gradual development of fibrotic scar tissue hinders muscle regeneration and leads to incomplete functional recovery. In the present study, increase of collagen fibrils was found. There is evidence that transforming growth factor $\beta 1$ (TGF- $\beta 1$) is a major stimulator of fibrosis in skeletal muscle (25, 26). Collagen deposition has also been demonstrated in the heart of DOCA-salt hypertensive rats, mediated by an endothelin-dependent component (27), and reactive oxygen species (ROS) also produce deposition of extracellular matrix proteins, such as collagen and fibronectin (28).

Muscle damage in hypertension may be due to the reduction in blood flow secondary to vascular changes. However, the multiple factors that can affect vessels in hypertension could eventually have a direct effect on skeletal muscle. For example, insulin resistance has been proposed as the cause for the suppression in muscle fibre regeneration in skeletal muscle grafts in SHR, in the presence of recovered muscle vascularization (29). Many factors have been involved in vascular pathology in hypertension, as oxidative and nitrosative stress, inflammation, and activation of the renin-angiotensin-aldosterone system (28, 30, 31). The capillary and muscle alterations found in the DOCA-salt rats (4) were more marked than those found in the present study in the SHR. The various degrees of activation of the mentioned mechanisms can probably explain the differences between the SHR and DOCA-salt hypertensive rats. In a study comparing the superoxide anion formation in vascular tissues of these two models of hypertension, it was slightly greater in SHR aorta and smooth muscle cells, but superoxide dismutase was only decreased in aorta in the DOCA-salt rats (32).

In conclusion, the present work demonstrates in SHR muscle capillary alterations indicative of degeneration, and focal

damage of structure with defective repair producing fibrosis in the EDL and soleus muscles. The changes were similar to those found in quadriceps muscle of no treated spontaneously hypertensive men. The lack of anatomical rarefaction in SHR may be explained by the activation of different pathologic pathways compared with other models of hypertension.

ACKNOWLEDGEMENTS

This study was supported by a grant from the Consejo de Desarrollo Científico y Humanístico of the Central University of Venezuela (No. 09-11.4571.2004).

REFERENCES

1. **Prewitt RL.** Autoregulation of blood flow, endothelial nitric oxide synthase and microvascular rarefaction. *J Hypertension* 2002; 20:177-178.
2. **Prewitt RL, Chen IH, Dowell R.** Development of microvascular rarefaction in the spontaneously hypertensive rat. *Am J Physiol* 1982; 243:H243-H251.
3. **Hernández N, Torres SH, Finol HJ, Vera O.** Capillary changes in skeletal muscle of patients with essential hypertension. *Anat Rec* 1999; 256:425-432.
4. **Hernández N, Torres SH, Finol HJ, Sosa A, Cierco M.** Capillary and muscle fiber type changes in DOCA-salt hypertensive rats. *Anat Rec* 1996; 246: 208-216.
5. **Chen II, Prewitt RL, Dowell RF.** Microvascular rarefaction in spontaneously hypertensive rats cremaster muscle. *Am J Physiol* 1981; 241:H306-H310.
6. **Greene AS, Lombard J, Cowley AW Jr, Hansen-Smith FH.** Microvessel changes in hypertension measured by *Griffonia simplicifolia* I lectin. *Hypertension* 1990; 15:779-783.
7. **Gray SD.** Histochemical analysis of capillary and fiber-type distributions in skeletal muscles of spontaneously hypertensive rats. *Microvase Res* 1988; 36(3):228-238.

8. **Ben Bachir-Lamrini L, Sempore B, Mayet MH, Favier RJ.** Evidence of a slow-to-fast fiber type transition in skeletal muscle from spontaneously hypertensive rats. *Am J Physiol* 1990; 258(2):R352-357.
9. **Saito YT, Sakanaki T, Ono Z, Sato K, Yagi A, Sakamoto H, Murata H.** Alterations of skeletal muscle fiber types and microvasculature in renovascular hypertensive rats [Abstract]. *Proc 5th World Congr Microcirc* 1991; 561:94.
10. **Bruschi G, Minari M, Bruschi ME, Tacinelli L, Milani B, Cavatorta A, Borghetti A.** Similarities of essential and spontaneous hypertension. Volume and number of blood cells. *Hypertension* 1986; 8:983-989.
11. **Friedman SM, Nakashima M, Mar MA.** Morphological assessment of vasoconstriction and vascular hypertrophy in sustained hypertension in the rat. *Microvasc Res* 1971; 3:416-425.
12. **Brooke MH, Kaiser KK.** Muscle fiber types: How many and what kind? *Arch. Neurol* 1970; 23:369-379.
13. **Andersen P.** Capillary density in skeletal muscle of man. *Acta Physiol Scand* 1975; 95:203-205.
14. **Frisbee JC.** Hypertension-independent microvascular rarefaction in the obese Zucker rat model of the metabolic syndrome. *Microcirculation* 2005; 12:383-392.
15. **Losada M, Torres SH, Hernández N, Lippo M, Sosa A.** Muscle arteriolar and venular reactivity in two models of hypertensive rats. *Microvasc Res* 2005; 69:142-148.
16. **Finol HJ, Muller B, Torres SH, Domínguez JJ, Perdomo P, Montes de Oca I.** Ultrastructural abnormalities in muscular vessels of hyperthyroid patients. *Acta Neuropathol (Berl)* 1986; 71:64-69.
17. **Vlodavsky EA, Ludatscher RM, Sabo E, Kerner H.** Evaluation of muscle capillary basement membrane in inflammatory myopathy. A morphometric ultrastructural study. *Virchows Arch* 1999; 435:58-61.
18. **Makitie J.** Skeletal muscle capillaries in intermittent claudication. *Arch Pathol Lab Med* 1977; 101:500-503.
19. **Cohen MP, Yu-Wu V.** Age-related changes in non-enzymatic glycosylation of human basement membranes. *Exp Gerontol* 1983; 18(6):461-469.
20. **Dosso AA, Leuenberger PM, Rungger-Brändle E.** Remodelling of retinal capillaries in the diabetic hypertensive rats. *Invest. Ophthalmol Vis Sci* 1999; 40: 2405-2410.
21. **Mulvany MJ, Aalkjaer C.** Structure and function of small arteries. *Physiol Rev* 1990; 70:921-961.
22. **Schiffrin EL.** Reactivity of small blood vessels in hypertension: relation with structural changes. State of the art lecture. *Hypertension* 1992; (19) [Suppl II]:II1-II9.
23. **Hirschi KK, D'Amore PA.** Pericytes in the microvasculature. *Cardiovasc Res* 1996; 32:687-698.
24. **Chargé SBP, Rudnicki MA.** Cellular and molecular regulation of muscle regeneration. *Physiol Rev* 2004; 84:209-238.
25. **Border WA, Noble NA.** Transforming growth factor beta in tissue fibrosis. *N Engl J Med* 1994; 331:1286-1292.
26. **Li Y, Foster W, Deasy BM, Chan Y, Prisk V, Tang Y, Cummins J, Huard J.** Transforming growth factor- β 1 induces the differentiation of myogenic cells into fibrotic cells in injured skeletal muscle. A key event in muscle fibrogenesis. *Am J Pathol* 2004; 164:1007-1019.
27. **Ammarguella FZ, Gannon PO, Amiri F, Schiffrin EL.** Fibrosis, matrix metalloproteinases, and inflammation in the heart of DOCA-salt hypertensive rats: role of ET(A) receptors. *Hypertension* 2002; 39:679-684.
28. **Touyz RM, Schiffrin EL.** Reactive oxygen species in vascular biology: implications in hypertension. *Histochem. Cell Biol* 2004; 122:339-352.
29. **Carlsen RC, Kerlin D, Gray SD.** Regeneration and revascularization of a nerve-intact skeletal muscle graft in the spontaneously hypertensive rat. *Am J Physiol* 1996; 270:R153-61.
30. **Joffe HV, Adler GK.** Effect of aldosterone and mineralocorticoid receptor blockade on vascular inflammation. *Heart Fail Rev* 2005; 10:31-37.

-
31. **Young M, Funder JW.** Esplerenone, but not steroid withdrawal, reverses cardiac fibrosis in deoxycorticosterone/salt-treated rats. *Endocrinology* 2004; 145:3153-3157.
 32. **Wu R, Millette E, Wu L, De Champlain J.** Enhanced superoxide anion formation in vascular tissues from spontaneously hypertensive and deoxycorticosterone acetate-salt hypertensive rats. *J Hypertension* 2001; 19:741-748.